

Macrophagic myofasciitis: an atypical presentation for a rare disease with a challenging approach

Rita Dias¹, Raquel Faria^{2,3}, Diogo Ribeiro⁴, Carlos Vasconcelos^{2,3}

¹Internal Medicine Department, Oporto University Hospital Center, Portugal

²Clinical Immunology Unit, Oporto University Hospital Center, Portugal

³Unit for Multidisciplinary Research in Biomedicine (UMIB) – ICBAS, Oporto University, Portugal

⁴Abel Salazar Institute of Biomedical Sciences (ICBAS), Oporto University, Portugal

Abstract

Macrophagic myofasciitis (MMF) is a rare immune-mediated myopathy that seems to be triggered by aluminium hydroxide adjuvant used in vaccines. Its presentation is relatively heterogeneous and treatment with steroids leads to improvement, although there is little evidence regarding the role of other immunosuppressants. The histological findings in MMF seem to be the result of an abnormal presence in the inoculation site of aluminium, which can induce an immune-mediated muscular disease in susceptible persons.

The authors describe the case of a patient with an atypical presentation of macrophagic myofasciitis, with histological confirmation in a muscle biopsy distant from the inoculation site, and a good therapeutic response to tacrolimus and mycophenolate mofetil, as well as a discussion on the pathologic basis, controversies and emerging treatments for this condition.

Key words: macrophagic myofasciitis, vaccines, aluminium hydroxide adjuvant, tacrolimus, mycophenolate mofetil, ASIA.

Introduction

Macrophagic myofasciitis (MMF) is an emerging condition triggered by exposure to aluminium adjuvants in genetically predisposed individuals, manifested with unspecific symptoms [1, 2].

The histological findings in MMF seem to be the result of an abnormal presence in the inoculation site of aluminium used as a vaccine adjuvant, which can induce an immune-mediated muscular disease in susceptible persons [1], and the pathophysiologic basis seems to be a sustained activation of the immune system, with permanent delivery of inflammatory cytokines and autoantibodies [3]. Until now, these findings have been only described in the vaccine inoculation site.

The authors present a case of a patient with pathognomonic histological characteristic of MMF in a distant location from the inoculation site, which may be a con-

sequence of a phagocytic process by macrophages that escape from the immunization site to lymph nodes and tissues [4]. Also, there are no consistent data about the optimal treatment of this condition, but this case highlights the possible role of tacrolimus and mycophenolate mofetil in inducing remission of the disease.

Objective and methods

The aim of this paper is to present the clinical approach of macrophagic myofasciitis, discussing the controversies about its existence and presenting the therapeutic difficulties to achieve remission.

The case study is presented as a basis for discussion and literature search on PubMed and World Health Organization (WHO) databases, using the following combination of words: “macrophagic myofasciitis”, “ASIA”, “vaccines”, “adjuvants”, “tacrolimus” and “mycophenolate mofetil”.

Address for correspondence:

Rita Dias, Internal Medicine Department, Oporto University Hospital Center, Largo Professor Abel Salazar, 4099-001 Oporto, Portugal, e-mail: rita.ribeiro.d@gmail.com

Submitted: 21.02.2020; Accepted: 29.05.2020

Case report

A 15-year-old female patient presented to our department with a history of distal myalgia in both forearms, bilateral tibiotarsal arthritis and intermittent fever (maximum 39°C), six months after meningococcal group C vaccination (excipient: aluminium hydroxide) in the deltoid muscle. The laboratory evaluation showed an increased erythrocyte sedimentation rate (ESR) (> 90 mm/h), mild anaemia (11.1 g/dl) and normal values of creatine kinase (< 200 U/l). Anti-nuclear antibodies (ANA) were positive (1/320 with mottled pattern) as well as the rheumatoid factor (2 times the upper limit), while anti-extractable nuclear antigen (ENA), anti-dsDNA and anti-citrullinated protein antibodies were all negative. The patient had increased levels of C3 and normal C4, polyclonal gammopathy (IgG 2 g/dl) and elevated β -2-microglobulin (3 mg/dl).

Considering the clinical presentation and laboratory results, in the absence of criteria to fulfil the diagnosis of any distinct connective tissue disease, we assumed the diagnosis of undifferentiated connective tissue disease (UCTD). The patient was treated with prednisolone 7.5 mg/day, with complete resolution of symptomatic and laboratory abnormalities.

Twenty-two months later (almost 3 years after inoculation), the patient presented again with asthenia and

myalgia, predominantly in the right forearm, oedema and functional disability. The patient had neither fever nor any abnormal laboratory finding. The magnetic resonance imaging (MRI) of the right forearm (Fig. 1) revealed signs of inflammation in the superficial and deep flexor muscles of the forearm, suggesting myositis. A muscle biopsy was performed in the flexor compartment of the right forearm (Fig. 2), which showed extensive fibrosis and an inflammatory process involving the endomysium, perimysium and fascia, with macrophages towels (Figs. 2A and 2B).

Considering these results and the overall clinical presentation of the patient, macrophagic myofasciitis (MMF) was assumed. We restarted prednisolone with improvement of symptoms and resolution of inflammatory signs. For steroid weaning, azathioprine was introduced and physical rehabilitation was started. However, due to leukopenia, neutropenia and headache, an adequate dose of azathioprine was never possible to achieve, nor was it possible to wean steroids due to pain recurrence.

Despite initial improvement, clinically detectable inflammation remained in the right forearm with local thickening. After nine months of treatment with no significant improvement, we switched azathioprine to methotrexate in increasing doses, with clear improvement of the right forearm thickening. Eighteen months later, clinical myo-

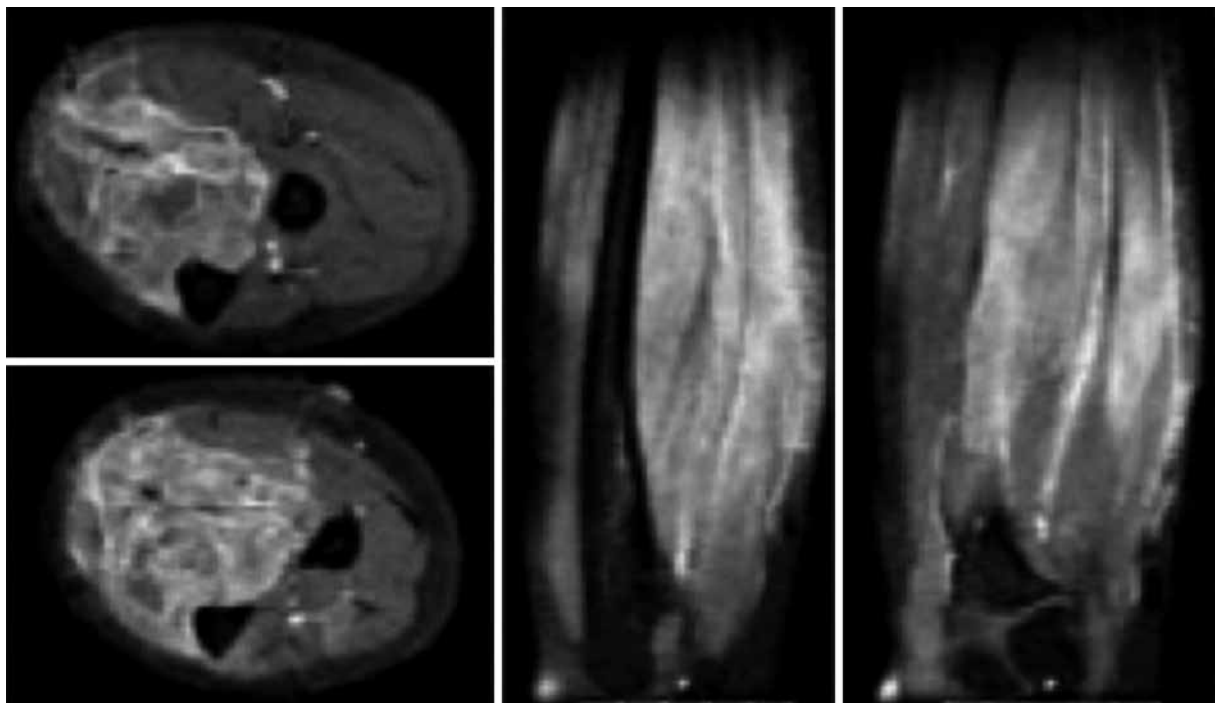


Fig. 1. MRI of right forearm: diffuse hyperintensity of the forearm flexor muscles, including the superficial and deep compartments, extending along the corresponding myotendinous joints with intense muscle uptake of gadolinium.

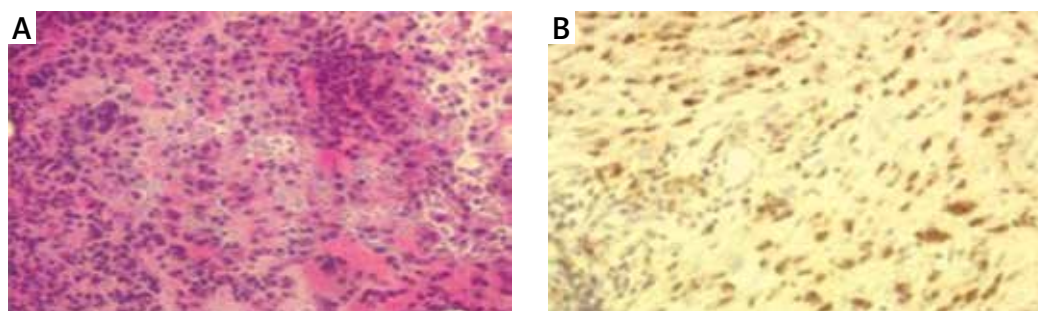


Fig. 2. Muscle biopsy of flexor muscle of forearm: extensive fibrosis and an inflammatory process involving the endomysium, perimysium and fascia, with macrophages towels, some lymphocytes and perivascular plasma cells, not identifying granulomas (A). The immunohistochemical test was strongly positive for CD68 (B).

fasciitis, muscle pain and functional impotence recurred. The laboratorial and MRI inflammation was controlled with a temporary increase in prednisolone.

After two years of reasonable symptomatic control with methotrexate (maximum 17.5 mg/week) and low dose prednisolone, there was a relapse with fever, increased ESR, pain, skin and muscular thickening of the contralateral forearm. We started add-on mycophenolate mofetil (500 mg/day) with a sustained improvement, but a few months later, the dose was decreased due to neutropenia with consequent worsening of symptoms.

A year later, we switched methotrexate to tacrolimus (Tac) with mycophenolate and finally it was possible to wean prednisolone. After some adjustments in the immunosuppressive therapy, the patient currently has normal muscle strength and mild muscular pain, despite moderate functional disability, on prednisolone 5 mg/day, mycophenolate mofetil 250 mg/day and tacrolimus 5 mg/day, hydroxychloroquine (800 mg/week), while keeping on a programme of regular physical rehabilitation.

Results of data searching

The authors analysed similar cases reported in the literature and studies regarding the pathologic mechanisms of autoimmune/autoinflammatory syndrome induced by adjuvants (ASIA) syndrome and MMF. Since the first description in 1998, there have been case reports and case series describing the clinical and histopathologic features of patients with MMF and associations with other immune disease. No reports of bilateral MMF were found in our revision, nor accurate data related to its treatment.

Discussion

Macrophagic myofasciitis represents an uncommon immune-mediated aluminium-induced myopathic disease, with a clinical presentation of unspecific diffuse

symptoms with delayed onset after vaccination, and despite its well-defined long-term persistent histological characteristics in the vaccine inoculation site, it is not totally clear how these correlate with the clinical patterns seen in these patients [1, 5]. It was first described in 1998, by French pathologists, as a condition of unknown cause, characterized by a pathognomonic lesion at muscle biopsy [3].

Later, in 2001, Shoenfeld and Agmon-Levin [6] used the term “autoimmune/autoinflammatory syndrome induced by adjuvants” to include five immune-mediated diseases with shared clinical and pathogenic characteristics, all related to exposure to adjuvants: the macrophagic myofasciitis syndrome, the Gulf War syndrome, the sick building syndrome, silicosis, and post-vaccination autoimmune phenomena.

Other conditions have been associated with adjuvants, as assessed by a recent review of patients with myalgic encephalomyelitis/chronic fatigue syndrome in France, supporting the view that this recognized condition may be, at least in a percentage of cases, a result of adverse effects of vaccines containing poorly degradable particulate aluminium adjuvants [7].

Immunologic adjuvants are substances added to vaccines to modulate the immune response in various ways. Acting as a vehicle, they carry antigens to antigen-presenting cells, to accelerate, enhance or prolong antigen-specific immune responses [8, 9]. Various adjuvants have been used for decades, including aluminium salts, as the most commonly used adjuvant in human and veterinary vaccines. Aluminium adjuvants have been used in vaccines against hepatitis A and B virus, tetanus toxoid, herpes papilloma virus and for subcutaneous allergy immunotherapy, acting as a potent stimulator of humoral response, shifting the immune responses toward a Th-2 profile [10].

The notion that immune adjuvants may contribute to the development of immune-mediated diseases is older than the description of ASIA. At least since 1980,

there have been reports mentioning autoimmune symptoms suggestive of connective tissue disease, following silicone administration [11, 12]. Additional evidence has supported the potential role of adjuvants in the development of autoimmunity in murine models, inducing an increase in inflammatory cytokine production associated with the appearance of lupus-related autoantibodies [13, 14].

The conditions included in the term ASIA share not only the exposure to an immune adjuvant, but also a genetically susceptible substrate, with a greater or lesser additional environmental impact. Particularly in MMF, the impact of the adjuvant seems to be particularly important in subjects who are genetically susceptible, or in subjects who were co-exposed to more than one trigger, such as exposure to another deleterious environmental factor (i.e. infectious agent) or to more than one adjuvant [15–18]. However, as they are “recent” diseases, there are contradictory opinions regarding their existence as single entities, and the diagnosis is challenging. There have been proposed several major and minor criteria that may help in the diagnosis of ASIA, although further validation is required (Table I).

Since its first description, conflicting reports have been published and the WHO considered that there is no evidence to suggest that MMF is a specific illness [19–22]. In the last years, some authors also have been refuting the existence of the conditions included in ASIA. The diagnostic criteria for ASIA are extremely broad (Table I) and other conditions, mainly immune diseases, may fit those criteria, as argued by Ameratunga et al. [23]. In effect, the prevalence of immune diseases

seems to be significantly higher in patients with ASIA, and some authors have hypothesised that this relation may be part of the disease spectrum, or related to the genetic predisposing profile [22, 24–26].

In a recent review paper regarding the current evidence for ASIA syndrome and the controversy over its validity, the authors reinforced two crucial aspects of scientific evidence, already mentioned above in this discussion: the interplay entailing a genetically susceptible person, exposed to an adjuvant, and the role of vaccines in immune stimulation, possibly triggering autoimmunity by molecular mimicry [22].

Patients with MMF are usually middle-aged adults, with systemic manifestations that include diffuse myalgias, arthralgia, fatigue, muscle weakness, chronic fatigue and fever. There are also reports of related demyelinating and cognitive disorders. Many patients also present elevated creatine kinase and erythrocyte sedimentation rate as well as autoantibodies, and myopathic EMG changes [27–29]. The temporal association between the vaccination, the histological detection and the beginning of related symptoms is variable, ranging from a few months up to 15 years. In practice, MMF is hypothesized when the time from the last immunization to detection of histological characteristics is longer than 18 months, but the symptoms may begin earlier [30–32].

Histologically, MMF is characterized by infiltration of the epimysium, perimysium and perifascicular endomysium by periodic acid-Schiff’s reagent (PAS)-positive large macrophages, lymphocytic infiltrates, and muscle fibre damage. These findings seem to be the result of an abnormal presence in the inoculation site of alumin-

Table I. Diagnostic criteria for autoimmune/autoinflammatory syndrome induced by adjuvants (ASIA) (acc. to Shoenfeld and Agmon-Levin [6])

Major criteria
1. Exposure to an external stimulus (vaccine, infection, silicone), prior to clinical manifestations
2. Appearance of typical clinical manifestations: <ul style="list-style-type: none"> • myalgia, myositis, muscle weakness • arthralgia and/or arthritis • chronic fatigue, un-refreshing sleep, sleep disturbance • neurological manifestations (especially associated with demyelination), • cognitive impairment, memory loss • pyrexia, dry mouth
3. Removal of inciting agent induces improvement
4. Typical biopsy of involved organs
Minor criteria
1. The appearance of autoantibodies or antibodies directed at the suspected adjuvant
2. Other clinical manifestations (irritable bowel syndrome)
3. Specific HLA (HLA-DRB1, HLA-DQB1)
4. Evolvement of an autoimmune disease (multiple sclerosis, systemic sclerosis)

ium used as a vaccine adjuvant, which can induce an immune-mediated muscular disease in susceptible persons, resulting in sustained activation of the immune system and permanent delivery of inflammatory cytokines and autoantibodies. In addition, an important proportion of the particles injected in the muscle are rapidly phagocytosed by macrophages and escape from the immunization site to lymph nodes and tissues [1].

Aluminium biodistribution after inoculation is still unclear and there is a possibility of muscle damage at other places distant from the inoculation site. Although MMF histological lesions have been observed located at usual sites of vaccination – deltoid muscles (in adults) and quadriceps (in children) – there are few reports in which a second biopsy was made in a remote area of the injection, in these cases, showing no evidence MMF diffusion. Experiments performed in rodents have also shown that the intramuscular injection of aluminium hydroxide is accompanied by its diffusion in the entire body [3, 30, 33].

Our patient represents an atypical forearm localized form of MMF almost 3 years after the aluminium-containing vaccine, confirmed in MRI and with a biopsy in a muscle distant from the inoculation site, preceded by a systemic inflammatory flare, 6 months after vaccination. Due to the clinical heterogeneity of the reported cases of MMF and controversies on its real existence as a clinical entity, there is no recommended treatment. There are few reports on immunosuppressants use for symptomatic control.

In the presented case, the response was temporarily favourable to steroids, azathioprine, methotrexate, mycophenolate mofetil and finally combined therapy with Tac. The decision to use mycophenolate mofetil and Tac in this patient was based on evidence supporting their efficacy in other muscle inflammatory diseases and strengthens the potential role of these drugs in this condition. The concurrent use of Tac with mycophenolate has been shown to increase plasma levels of active mycophenolic acid, allowing a reduction in the mycophenolate dose, while achieving efficacy, and ultimately a reduction in adverse effects [34, 35].

According to our knowledge and review of the literature, the present case, as a background for wide discussion, is the first report of bilateral single specific muscle group involvement, distant from the inoculation site, and with a predominantly macrophagic infiltrate MMF's pathognomonic muscle biopsy.

Conclusions

In this review based on a case report the authors present an atypical case of MMF and its approach, and discuss the characteristics and scientific controversies

about the disease. Additionally to these questions, as a rare disease, MMF may raise diagnostic and treatment challenges, having an important burden in respect to patients' quality of life.

This case-based review can be a valuable source in supporting the existence of MMF, as there is no other known clinical and pathologic entity described to date that better explains these abnormalities, and may help to decide and guide future research studies into the best therapeutic approach for these patients.

Acknowledgements

We thank Professor Dr. Melo Pires (Neuropathology Unit and Department of Neurology of Centro Hospitalar e Universitario do Porto), for having kindly provided the histological images.

The authors declare no conflict of interest.

References

- Gherardi RK, Authier FJ. Macrophagic myofasciitis: characterization and pathophysiology. *Lupus* 2012; 21: 184-189, DOI: 10.1177/0961203311429557.
- Israeli E, Agmon-Levin N, Blank M, Shoenfeld Y. Macrophagic myofasciitis a vaccine (alum) autoimmune-related disease. *Clin Rev Allergy Immunol* 2011; 41: 163-168, DOI: 10.1007/s12016-010-8212-4.
- Gherardi RK, Coquet M, Cherin P, et al. Macrophagic myofasciitis lesions assess long-term persistence of vaccine – derived aluminium hydroxide in muscle. *Brain* 2001; 124: 1821-1831, DOI: 10.1093/brain/124.9.1821.
- Chkheidze R, Burns DK, White CL, et al. Morin Stain Detects Aluminum-Containing Macrophages in Macrophagic Myofasciitis and Vaccination Granuloma With High Sensitivity and Specificity. *J Neuropathol Exp Neurol* 2017; 76: 323-331, DOI: 10.1093/jnen/nlx011.
- Perricone C, Colafrancesco S, Mazar RD, et al. Autoimmune/inflammatory syndrome induced by adjuvants (ASIA) 2013: Unveiling the pathogenic, clinical and diagnostic aspects. *J Autoimmun* 2013; 47: 1-16, DOI: 10.1016/j.jaut.2013.10.004.
- Shoenfeld Y, Agmon-Levin N. 'ASIA' – autoimmune/inflammatory syndrome induced by adjuvants. *J Autoimmun* 2011; 36: 4-8, DOI: 10.1016/j.jaut.2010.07.003.
- Gherardi RK, Crépeaux G, Authier FJ. Myalgia and chronic fatigue syndrome following immunization: macrophagic myofasciitis and animal studies support linkage to aluminum adjuvant persistency and diffusion in the immune system. *Autoimmun Rev* 2019; 18: 691-705, DOI: 10.1016/j.autrev.2019.05.006.
- Awate S, Babiuk LA, Mutwiri G. Mechanisms of action of adjuvants. *Front Immunol* 2013; 4: 114, DOI: 10.3389/fimmu.2013.00114.
- McKee AS, MacLeod MKL, Kappler JW, Marrack P. Immune mechanisms of protection: can adjuvants rise to the challenge? *BMC Biol* 2010; 8: 37, DOI: 10.1186/1741-7007-8-37.

10. Exley C, Siesjö P, Eriksson H. The immunobiology of aluminium adjuvants: how do they really work? *Trends Immunol* 2010; 31: 103-109, DOI: 10.1016/j.it.2009.12.009.
11. Kumagai Y, Shiokawa Y, Medsger TA Jr., Rodnan GP. Clinical spectrum of connective tissue disease after cosmetic surgery. Observations on eighteen patients and a review of the Japanese literature. *Arthritis Rheum* 1984; 27: 1-12, DOI: 10.1002/art.1780270101.
12. Sergott TJ, Limoli JP, Baldwin CM Jr., Laub DR. Human adjuvant disease, possible autoimmune disease after silicone implantation: a review of the literature, case studies, and speculation for the future. *Plast Reconstr Surg* 1986; 78: 104-114, DOI: 10.1097/00006534-198607000-00018.
13. Satoh M, Kuroda Y, Yoshida H, et al. Induction of lupus autoantibodies by adjuvants. *J Autoimmun* 2003; 21: 1-9, DOI: 10.1016/s0896-8411(03)00083-0.
14. Kuroda Y, Nacionales DC, Akaogi J, et al. Autoimmunity induced by adjuvant hydrocarbon oil components of vaccine. *Biomed Pharmacother* 2004; 58: 325-337, DOI: 10.1016/j.biopha.2004.04.009.
15. Agmon-Levin N, Shoenfeld Y. Chronic fatigue syndrome with autoantibodies –the result of an augmented adjuvant effect of hepatitis-B vaccine and silicone implant. *Autoimmun Rev* 2008; 8: 52-55, DOI: 10.1016/j.autrev.2008.07.026.
16. Burek CL, Talor MV. Environmental triggers of autoimmune thyroiditis. *J Autoimmun* 2009; 33: 183-189, DOI: 10.1016/j.jaut.2009.09.001.
17. Arango MT, Perricone C, Kivity S, et al. HLA-DRB1 the notorious gene in the mosaic of autoimmunity. *Immunol Res* 2017; 65: 82-98, DOI: 10.1007/s12026-016-8817-7.
18. Guis S, Mattei JP, Nicoli F, et al. Identical twins with macrophagic myofasciitis: genetic susceptibility and triggering by aluminic vaccine adjuvants? *Arthritis Rheum* 2002; 47: 543-545, DOI: 10.1002/art.10666.
19. WHO. Macrophagic myofasciitis and aluminium-containing vaccines. *WHO Weekly Epidemiological Record* 1999.
20. WHO. Questions and Answers about macrophagic myofasciitis (MMF), 2008.
21. Goullé JP, Grangeot-Keros L. Aluminum and vaccines: Current state of knowledge. *Med Mal Infect* 2020; 50: 16-21, DOI: 10.1016/j.medmal.2019.09.012.
22. Segal Y, Dahan S, Sharif K, et al. The value of Autoimmune Syndrome Induced by Adjuvant (ASIA) – Shedding light on orphan diseases in autoimmunity. *Autoimmun Rev* 2018; 17: 440-448, DOI: 10.1016/j.autrev.2017.11.037.
23. Ameratunga R, Gillis D, Gold M, et al. Evidence Refuting the Existence of Autoimmune/Autoinflammatory Syndrome Induced by Adjuvants (ASIA). *J Allergy Clin Immunol Pract* 2017; 5: 1551-1555.e1, DOI: 10.1016/j.jaip.2017.06.033.
24. Liang R, Liu A, Perumpail RB, et al. Advances in alcoholic liver disease: An update on alcoholic hepatitis. *World J Gastroenterol* 2015; 21: 11893-11903, DOI: 10.3748/wjg.v21.i42.11893.
25. Authier FJ, Sauvat S, Champey J, et al. Chronic fatigue syndrome in patients with macrophagic myofasciitis. *Arthritis Rheum* 2003; 48: 569-570, DOI: 10.1002/art.10740.
26. Butnaru D, Shoenfeld Y. Adjuvants and lymphoma risk as part of the ASIA spectrum. *Immunol Res* 2015; 61: 79-89, DOI: 10.1007/s12026-014-8622-0.
27. Gherardi RK, Coquet M, Chérin P, et al. Macrophagic myofasciitis: an emerging entity. Groupe d'Etudes et Recherche sur les Maladies Musculaires Acquises et Dysimmunitaires (GERMMAD) de l'Association Française contre les Myopathies (AFM). *Lancet* 1998; 352: 347-352, DOI: 10.1016/s0140-6736(98)02326-5.
28. Exley C, Swarbrick L, Gherardi RK, Authier FJ. A role for the body burden of aluminium in vaccine-associated macrophagic myofasciitis and chronic fatigue syndrome. *Med Hypotheses* 2009; 72: 135-139, DOI: 10.1016/j.mehy.2008.09.040.
29. Authier FJ, Chérin P, Creange A, et al. Central nervous system disease in patients with macrophagic myofasciitis. *Brain* 2001; 124: 974-983, DOI: 10.1093/brain/124.5.974.
30. Gherardi RK, Authier FJ. Aluminum inclusion macrophagic myofasciitis: a recently identified condition. *Immunol Allergy Clin North Am* 2003; 23: 699-712, DOI: 10.1016/s0889-8561(03)00095-x.
31. Ryan AM, Bermingham N, Harrington HJ, Keohane C. Atypical presentation of macrophagic myofasciitis 10 years post vaccination. *Neuromuscul Disord* 2006; 16: 867-869, DOI: 10.1016/j.nmd.2006.07.017.
32. Santiago T, Rebelo O, Negrão L, Matos A. Macrophagic myofasciitis and vaccination: consequence or coincidence? *Rheumatol Int* 2015; 35: 189-192, DOI: 10.1007/s00296-014-3065-4.
33. Rigolet M, Aouizerate J, Couette M, et al. Clinical features in patients with long-lasting macrophagic myofasciitis. *Front Neurol* 2014; 5: 230, DOI: 10.3389/fneur.2014.00230.
34. Olivo Pallo PA, de Souza FHC, Miossi R, Shinjo SK. Mycophenolate mofetil in patients with refractory systemic autoimmune myopathies: case series. *Adv Rheumatol* 2018; 58: 34, DOI: 10.1186/s42358-018-0035-7.
35. Hanaoka H, Iida H, Kiyokawa T, et al. Mycophenolate mofetil treatment with or without a calcineurin inhibitor in resistant inflammatory myopathy. *Clin Rheumatol* 2019; 38: 585-590, DOI: 10.1007/s10067-018-4294-9.