

Takayasu's arteritis occurring under TNF blockers in a patient with spondyloarthritis: is it an association or a paradoxical effect?

Amel Rezgui , Maissa Thabet , Sahar Makki , Jihed Anoun , Imen Ben Hassine ,
Monia Karmeni , Fatma Ben Fredj , Anis Mzabi , Chedia Laouani 

Department of Internal Medicine, Sahloul Hospital, University of Sousse, Faculty of Medicine of Sousse, Tunisia

Abstract

Coexistence of spondyloarthritis (SpA) and Takayasu's arteritis is not a common finding, but such cases have been discussed, particularly in the context of choice of therapy. Inhibition of inflammation by tumor necrosis factor inhibitors (TNFi) is a key aspect of the treatment of SpA and also positive effects of such treatment in concomitant large vessel vasculitis have been reported. However, TNFi is also associated with the possibility of initiating vasculitis.

The present article based on a case study and the available literature is an attempt to discuss coexistence of these two diseases and the impact of treatment with biological drugs from the anti-TNF group in the course of SpA with Takayasu's arteritis.

Key words: ankylosing spondylitis, Takayasu's arteritis, tumor necrosis factor.

Introduction

Takayasu's arteritis (TA) is a rare granulomatosis of large-vessel vasculitis with an unknown etiology. The association of TA and spondyloarthritis (SpA) has been reported occasionally in the literature and the authors suggested that both diseases could coexist in a single patient [1, 2].

Spondyloarthritis is a wider spectrum of diseases, which contains ankylosing spondylitis, axial spondyloarthritis, enteropathic spondyloarthritis, peripheral spondyloarthritis, psoriatic arthritis and reactive arthritis. The treatment of SpA depends on involvement of axial or peripheral joints [3].

Tumor necrosis factor inhibitors (TNFi) are the basic biological treatment of SpA in the cases of insufficient treatment with non-steroidal anti-inflammatory drugs (NSAID) in the course of axial involvement and disease-modifying antirheumatic drugs such as methotrexate or sulfasalazine in the case of peripheral joint involvement.

Undoubtedly, the high efficacy of TNFi in the treatment of SpA was confirmed. In the case of large vessels vasculitis, such treatment was also used. In some cases its significant effectiveness was reported, but there are

also contradictory observations and attention was drawn to the possibility of diagnosing e.g. TA after the introduction of TNFi treatment.

The aim of this article is to draw attention to the possible coexistence of SpA and TA and to discuss the use of TNFi in such cases.

Objective and methods

The aims of this case-based review were: to report a new case of TA that occurred after anti-TNF therapy in a patient with SpA and to perform a review of similar case reports (patients with TA and SpA or TA occurring under anti-TNFs).

The authors performed a systematic search of case reports or case series of patients with both TA and SpA or with TA occurring under anti-TNF in PubMed, Scopus and Google Scholar from the onset until October 2020 and using the following combination of words: *ankylosing spondylitis, Takayasu's arteritis, tumor necrosis factor*. The language of the chosen articles was restricted to English. The discussion was based on the case study and a literature review.

Address for correspondence:

Maissa Thabet, Department of Internal Medicine, Sahloul Hospital, University of Sousse, Faculty of Medicine of Sousse, Tunisia,
e-mail: maissa.thabet22@gmail.com

Submitted: 24.09.2020; Accepted: 20.01.2021

Case description

A 43-year-old man presented in 2015 with inflammatory back pain for 3 years. The patient's erythrocyte sedimentation rate (ESR) was 100 mm/hour and C-reactive protein (CRP) was 130 mg/l. Spine and pelvic MRI showed bilateral active sacroiliitis.

The diagnosis of spondyloarthritis, in its axial form, was established according to the Assessment of SpondyloArthritis International Society (ASAS) criteria.

The patient received NSAID for one year but finally without satisfactory clinical improvement according to the Bath Ankylosing Spondylitis Disease Activity Index (BASDAI) criteria and therefore was treated with adalimumab for two and a half years with complete remission.

In January 2019, the patient presented a transient ischemic attack with a normal cerebral angioscan. On admission, the patient was asymptomatic and the history gave no clue of an ongoing vasculitis. The clinical examination revealed comparable normal blood pres-

sure values in both arms, and slightly decreased radial and pedal pulses. The pulse in the extremities was hardly discernible, with presence of a bilateral umbilical bruit, bilateral carotid bruit and a right subclavian artery bruit.

The thoracic angio-CT showed the presence of multiple significant stenoses of the supraaortic arteries (right subclavian artery (Fig. 1) and both vertebral arteries, the thoracic and abdominal aorta. The digestive tract arteries (superior and inferior mesenteric artery) and both renal arteries were also constricted (Fig. 2), with celiac trunk stenosis of 60%.

The laboratory examinations showed elevated markers of inflammation (CRP: 70 mg/l, ESR: 55 mm/h). The diagnosis of TA was retained and it was stage 5 according to the Tokyo 1994 classification.

Adalimumab was stopped and the patient underwent a 3-day regimen of methylprednisolone (15 mg/kg/day) followed by a 1 mg/kg/day prednisone dose. Methotrexate (MTX) was maintained at the dose of 25 mg *p.o.* weekly. Under this treatment, a good response with

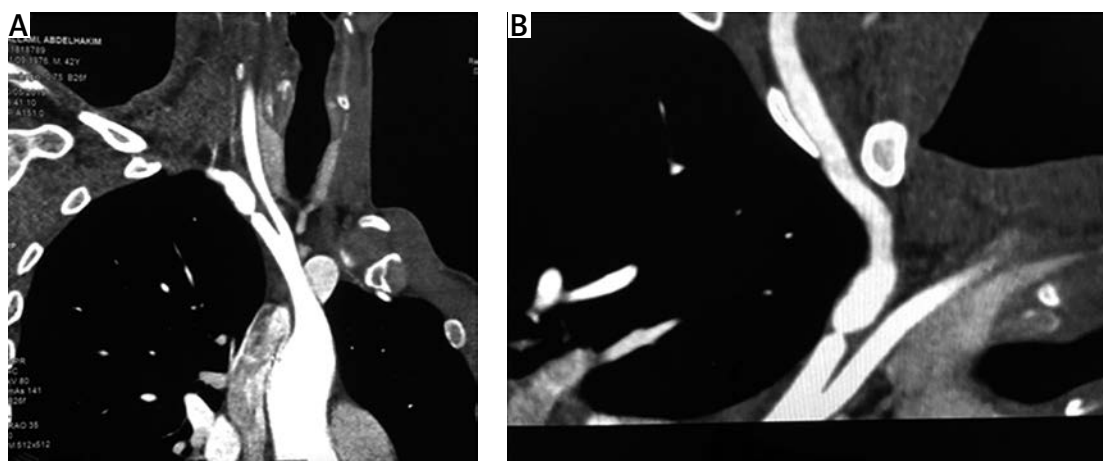


Fig. 1. Thoracic angio-CT showing right subclavian artery stenoses.

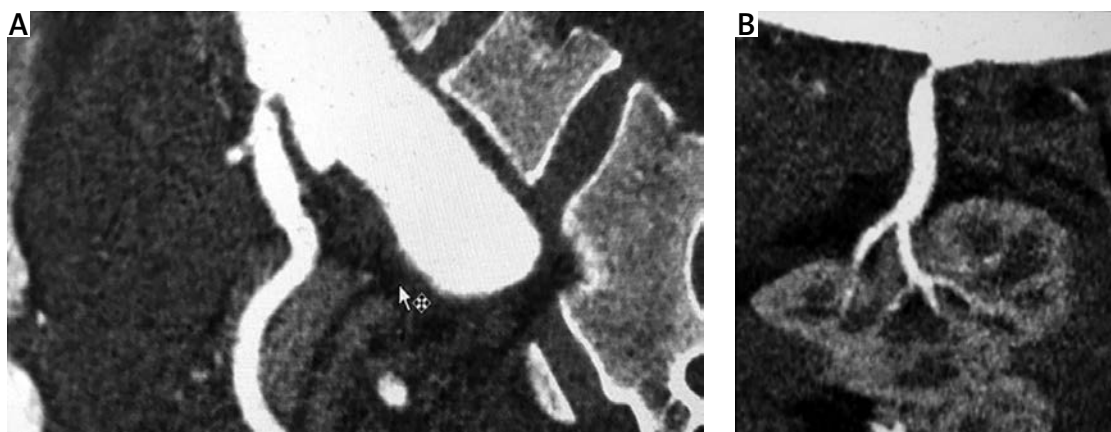

Fig. 2. Abdominal angio-CT showing superior mesenteric and renal arteries stenoses.

normalization of the inflammatory parameters was observed.

Discussion

We have described a patient who developed active TA inflammation despite being treated with a standard regimen of anti-TNFi for SpA.

Anti-TNFi therapy is highly effective for SpA and TA is usually treated with glucocorticoids, supplementing the therapy with immunosuppressive drugs such as MTX. Moreover, plasma levels of TNF- α are high in TA; thus, a large number of case series and observational studies have supported the premise that TNF inhibitors are highly effective and safe in patients with severe and refractory TA, with a prolonged sustained response [3, 4].

Anti-TNFs are currently recommended for the treatment of TA in the cases of corticosteroid-dependent or corticosteroid-resistant cases despite treatment with a non-biological immunosuppressive medication [5].

Some authors [6–8] reported cases of TA arising under TNFi therapy and propose a causal effect of the TNFi use on TA development. Others describe aortitis occurring under TNFi therapy [9].

The mechanism of this paradoxical side effect remains unclear and we still cannot determine the contribution of TNFi to the development of vasculitis. Nevertheless, this phenomenon might be related to immune complexes containing the drug which may be deposited on vessel walls in a disturbed immune homeostasis [6].

It is worth mentioning that paradoxical vasculitis is mainly limited to the skin, but in some cases, patients may experience the onset of an authentic systemic disease with renal, pulmonary and central and peripheral nervous system involvement [10].

Some authors have suggested that prevalence of TA in SpA and SpA in TA are both higher than in the general population [1, 11]. Gudbrandsson et al. [12] reported that a Norwegian population had a prevalence of 22 cases of TA per 106 in northern Europeans. The authors also observed a high frequency of SpA and Crohn's disease among patients with TA (7% and 8%, respectively, whereas the usual prevalence of SpA in a French population is estimated at 0.3%) [1].

In a recent study, Güzel et al. [13] enrolled 69 patients with TA. There were 14 (20.3%) patients who fulfilled the Assessment of SpondyloArthritis International Society criteria for Spondyloarthropathy.

Mielnik et al. [14] suggested that all epidemiological and pathological considerations lead to the hypothesis that patients with both TA and SpA diagnoses can present with extreme arterial involvement due to SpA which could be misclassified as TA.

All discussed results support an association between SpA and TA. Thus, coexistence of these diseases might be more than a coincidence, and so may be the case of our patient.

However, Rivière et al. [1] studied 14 patients and the chronology of introduction of TNFi in SpA patients and TA diagnosis; 11 cases out of 14 did not receive anti-TNF therapy before the TA diagnosis, thus excluding an anti-TNF- α role in the development of TA. The authors suggest that TA could represent another associated disease, which may be underdiagnosed in patients with a SpA. Moreover, among the 3 patients who received anti-TNF therapy before the diagnosis of TA, all were treated with etanercept (ETN) [1], which could mean that ETN could not prevent TA in those 3 patients [1].

The occurrence of both diseases may be explained by an antigenic analogy between the aorta and the entheses. Sherlock et al. [15] found in an animal model of SpA that the enthesopathy observed was linked with T lymphocytes (entheses-resident), which have a double-negative phenotype, and the interleukin 23 (IL-23) receptor. This can develop in the aortic root and valve, which are structurally similar to entheses. Thus, this phenomenon could explain in part the observations of aortitis occurring during SpA evolution and could explain the association between TA and SpA.

Conclusions

Spondyloarthritis is rarely associated with TA but this might not be a coincidence. Therefore, an exhaustive evaluation of all vessels with a clinical examination of all peripheral arterial pulses is crucial in SpA patients' follow-up. Also the implication of treatment with TNFi in the occurrence of TA associated with SpA was also suggested.

Retrospective analysis of large cohorts of patients suffering from SpA and TA may help to confirm a causative link. Also the effectiveness of TNFi treatment in such difficult cases should be more widely analyzed.

The authors declare no conflict of interest.

References

1. Rivière E, Arnaud L, Ebbo M, et al. Takayasu arteritis and spondyloarthritis: coincidence or association? A study of 14 cases. *J Rheumatol* 2017; 44: 1011–1017, DOI: 10.3899/jrheum.160762.
2. Ben Abdelghani K, Fazaa A, Ben Abdelghani et al. Chronic inflammatory rheumatism associated with Takayasu disease. *Ann Vasc Surg* 2013; 27: 353.e1-6, DOI: 10.1016/j.avsg.2011.11.048.
3. Comarmond C, Plaisier E, Dahan K, et al. Anti TNF-alpha in refractory Takayasu's arteritis: cases series and review of the

- literature. *Autoimmun Rev* 2012; 11: 678–684, DOI: 10.1016/j.autrev.2011.11.025.
4. Youngstein T, Peters JE, Hamdulay SS, et al. Serial analysis of clinical and imaging indices reveals prolonged efficacy of TNF- α and IL-6 receptor targeted therapies in refractory Takayasu arteritis. *Clin Exp Rheumatol* 2014; 32 (3 Suppl 82): S11–18.
 5. Clifford A, Hoffman GS. Recent advances in the medical management of Takayasu arteritis: an update on use of biologic therapies. *Curr Opin Rheumatol* 2014; 26: 7–15, DOI: 10.1097/BOR.0000000000000004.
 6. Souabni L, Ben Abdelghani K, Jradi S, Zakraoui L. Takayasu's arteritis occurring under TNF- α blockers: a new paradoxical effect? *BMJ Case Rep* 2014; 2014: bcr2014204226, DOI: 10.1136/bcr-2014-204226.
 7. Mariani N, So A, Aubry-Rozier B. Two cases of Takayasu's arteritis occurring under anti-TNF therapy. *Joint Bone Spine* 2013; 80: 211–213, DOI: 10.1016/j.jbspin.2012.07.015.
 8. Osman M, Aaron S, Noga M, Yacyshyn E. Takayasu's arteritis progression on anti-TNF biologics: a case series. *Clin Rheumatol* 2011; 30: 703–706, DOI: 10.1007/s10067-010-1658-1.
 9. Verhoeven F, Bossert M, Lohse-Walliser A, Balblanc JC. Aortitis during etanercept therapy for ankylosing spondylitis: finding the culprit. *Joint Bone Spine* 2012; 79: 524–526, DOI: 10.1016/j.jbspin.2012.03.006.
 10. Ramos-Casals M, Roberto-Perez-Alvarez, Diaz-Lagares C, et al. Autoimmune diseases induced by biological agents: a double-edged sword? *Autoimmun Rev* 2010; 9: 188–193, DOI: 10.1016/j.autrev.2009.10.003.
 11. Gan F, Fei Y, Li M, et al. The characteristics of patients having ankylosing spondylitis associated with Takayasu's arteritis. *Clin Rheumatol* 2014; 33: 355–358, DOI: 10.1007/s10067-013-2444-7.
 12. Gudbrandsson B, Molberg Ø, Garen T, Palm Ø. Prevalence, incidence and disease characteristics of Takayasu arteritis differ by ethnic background; data from a large, population based cohort resident in Southern Norway. *Arthritis Care Res (Hoboken)* 2017; 69: 278–285, DOI: 10.1002/acr.22931.
 13. Güzel Esen S, Armagan B, Atas N, et al. Increased incidence of spondyloarthropathies in patients with Takayasu arteritis: a systematic clinical survey. *Joint Bone Spine* 2019; 86: 497–501, DOI: 10.1016/j.jbspin.2019.01.020.
 14. Mielnik P, Hjelle AM, Nordeide JN. Coexistence of Takayasu's arteritis and ankylosing spondylitis may not be accidental – is there a need for a new subgroup in the spondyloarthritis family? *Modern Rheumatology* 2018; 28: 313–318, DOI: 10.1080/14397595.2017.1341592.
 15. Sherlock JP, Joyce-Shaikh B, Turner SP, et al. IL-23 induces spondyloarthropathy by acting on ROR- α + CD3+CD4–CD8– enthesal resident T cells. *Nat Med* 2012; 18: 1069–1076, DOI: 10.1038/nm.2817.