

## Skin melanoma in a rheumatoid arthritis patient treated with infliximab

*Czerniak złośliwy u chorej na reumatoidalne zapalenie stawów leczonej infliksymabem*

Janusz Jaworski, Paula Śliwińska-Stańczyk, Jan Krzysztof Łącki

Department of Connective Tissue Disease, Institute of Rheumatology, Warsaw  
Director Sławomir Maśliński, MD, PhD, Professor of Medicine

**Key words:** infliximab, rheumatoid arthritis, melanoma.

**Słowa kluczowe:** infliksymab, reumatoidalne zapalenie stawów, czerniak złośliwy.

### Summary

We present a case of skin melanoma in a 53-year-old patient with rheumatoid arthritis (RA) treated with infliximab and methotrexate. After 12 months of therapy during a routine examination before infusion of infliximab, the enlarging pigmented naevus on the skin of the right arm was prophylactically removed. Histopathological evaluation and immunohistochemistry led to the diagnosis of skin melanoma. We suggest that systematic control of the pigmented naevus during anti-TNF therapy should be strongly recommended.

Tumour necrosis factor  $\alpha$  (TNF- $\alpha$ ) plays an important role in the pathogenesis of rheumatoid arthritis (RA). Anti-TNF- $\alpha$  agents reduce disease activity of disease-modifying antirheumatic drug (DMARD) refractory RA patients, as monotherapy or in combination with methotrexate. There is evidence of an increased risk of serious infections in RA patients treated with anti-TNF blockers [1, 2]. However, it is not clear whether this kind of therapy increases the risk of malignancy [3-5].

### A case report

We report the development of malignant melanoma in a patient treated with infliximab for

### Streszczenie

W artykule opisano przypadek czerniaka złośliwego u 53-letniej kobiety chorej na reumatoidalne zapalenie stawów, leczonej metotreksatem i infliksymabem. Po 12 mies. terapii, w trakcie badania kontrolnego przed kolejnym wlewem infliksymabu, stwierdzono obecność powiększonego znamienia na skórze prawego barku. Znamię zostało profilaktycznie usunięte. Badanie histopatologiczne wykazało obecność czerniaka złośliwego. Zaleca się systematyczną kontrolę wszystkich zmian barwnikowych w trakcie terapii anti-TNF- $\alpha$ .

methotrexate resistant severe RA. A 53-year-old woman with 15-year history of seropositive RA was admitted to our department in July 2005 due to exacerbation of the RA process. In the past she was treated with Salazopyrin at 2 g/day (for 6 years). Three years before admission, therapy with methotrexate (15 mg/week) was started. Due to the lack of improvement, cyclosporine A (3 mg/kg/day) was added to the treatment for three months. That treatment was also ineffective. The therapy with cyclosporine was stopped and the patient was admitted to our department. The patient was qualified for infliximab therapy (3 mg/kg in weeks 0, 2, 6, and every 8 weeks). A rapid and satisfactory improvement

---

#### Address for correspondence:

Janusz Jaworski, Department of Connective Tissue Diseases, Institute of Rheumatology, Spartańska 1, 02-637 Warsaw, phone, fax +48 22 844 30 37, e-mail: jaworskij@ir.ids.pl

**Submitted:** 18.05.2009

in her general clinical condition was observed. After two weeks of therapy, morning stiffness disappeared, ESR and CRP normalized, the number of tender and swollen joints decreased – ACR70 was obtained (treatment with infliximab in combination with methotrexate was effective) (Table I).

In July 2006, during a routine examination before infusion of infliximab, an enlargement of the pigmented naevus on the skin of the right arm was observed. However, the skin around the naevus and its surface was in normal condition. The patient was referred to a dermatologist. Macroscopic features did not suggest malignant character of the skin lesion. The decision of prophylactic excision of the naevus was taken due to immunosuppressive treatment in the immunocompromised patient. On 31 August 2006 the 0.8 cm naevus was resected with a small (0.1–0.3 mm) margin of skin in the oncology outpatient clinic. Histopathological diagnosis was as follows: malignant melanoma epithelioides type SSMM of the skin. Clark III, Breslow 0.4 mm. Immunohistochemical typing revealed HMB45 (+); S100 (+); melanin (+) and confirmed the diagnosis of skin cancer. The immunosuppressive treatment was immediately discontinued. The patient was qualified only for radicalization of excision. The surgery was performed on 6 October 2006. A fragment of the skin and adipose tissue (3 × 2.5 × 1.7 cm) without malignant melanoma was removed. According to the oncologist's decision, the patient does not require either radio- or chemotherapy. Ultrasonography of the lymph nodes is to be performed every 4 months and self monitoring of the naevus is necessary. In March 2007, ultrasonography of lymph nodes and skin examination did not reveal any pathology (Fig. 1).

## Discussion

Many of the medications used in the treatment of RA may be associated with an increased risk of the development of malignancy [1, 4, 6]. There is some evidence of a dose-dependent increased risk of malignancies in patients with RA treated with anti-TNF antibody therapy [5, 7, 8]. Literature data confirm the fact that among patients with RA, the use of TNF inhibitors and prednisone were associated with an increased risk of non-melanoma skin cancers [5, 9, 10].

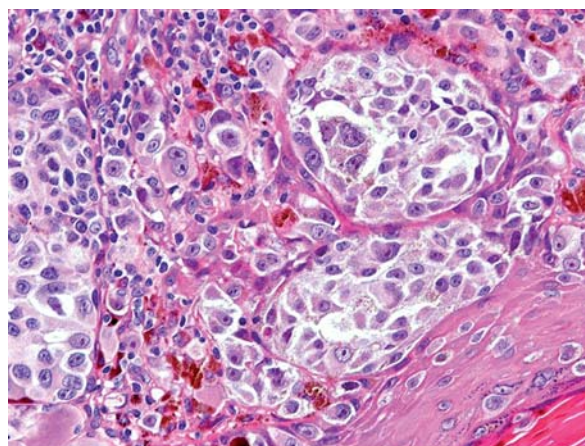
This case history is the first description of the development of melanoma during infliximab therapy in an RA patient. Systematic control of the pigmented naevus in our patient resulted in early diagnosis of melanoma. Despite the benign clinical features of the lesion, an excision was performed,

because of the increased risk of malignancy in RA during DMARD treatment. Histopathological evaluation and immunohistochemistry led to the diagnosis of skin melanoma. The skin cancer was diagnosed before the neoplastic process became generalized [3, 6, 10, 11].

**Table I.** Clinical characteristics of patient

*Tabela I. Charakterystyka kliniczna pacjentki*

Symptom	Before treatment	After treatment
ESR (mm/h)	63	15
CRP (mg/l)	47	0
number of tender joints	17	0
number of swollen joints	15	0
morning stiffness (h)	4	0
VAS (mm)	68	0
DAS	7.25	1.9



**Fig. 1.** Histology of the skin naevus of RA patients treated with infliximab with presence of melanoma epithelioides type SSMM of the skin, Clark III, Breslow 0.4 mm. Immunohistochemical typing showed HMB45 (+), S100 (+), melanin (+) and confirmed the diagnosis of skin melanoma.

**Ryc. 1.** Badanie histopatologiczne znamienia barwnikowego u pacjentki z RZS leczonej infliksymabem z obecnością czerniaka złośliwego skóry typu SSMM, Clark III, Breslow 0,4 mm. Typowanie immunohistochemiczne wykazało HMB45 (+), S100 (+), melanina (+) i potwierdziło obecność czerniaka skóry.

The long-term immunosuppressive effects of TNF- $\alpha$  blockers are unknown. Treatment with biological agents is still too recent for a full knowledge of its long-term safety. Appropriate follow-up is required to define its long-term effect on malignancies and other side effects [12].

The skin changes in our patient appeared 12 months after the onset of therapy. We have no evidence that the described malignancy is directly connected to the applied therapy. However, it seems to us that systematic control of the pigmented naevus during anti-TNF therapy should be strongly recommended. The prophylactic excision of suspected skin lesions can save the lives of our patients.

### References

1. Bovenschen HJ, Tjioe M, Vermaat H, et al. Induction of eruptive benign melanocytic naevi by immune suppressive agents, including biologicals. *Br J Dermatol* 2006; 154: 880-884.
2. Lipsky PE, Desiree MFM, van der Heijde MD, et al. Infliximab and methotrexate in the treatment of rheumatoid arthritis. *N Engl J Med* 2000; 343: 1594-1602.
3. Geborek P, Bladstrom A, Turesson C, et al. Tumor necrosis factor blockers do not increase overall tumor risk in patients with rheumatoid arthritis, but may be associated with an increased risk of lymphomas. *Ann Rheum Dis* 2005; 64: 699-703.
4. Mellekjær L, Line MS, Gridly G. Rheumatoid arthritis and cancer risk. *Eur J Cancer* 1996; 32A: 1753-1757.
5. Bucher C, Degen L, Dirnhofer S, et al. Biologics in inflammatory disease: infliximab associated risk of lymphoma development. *Gut* 2005; 54: 732-733.
6. Bakland G, Nossent H. Acute myelogenous leukemia following etanercept therapy. *Rheumatology* 2003; 42: 900-901.
7. Bongartz T, Sutton AJ, Sweeting MJ, et al. Anti-TNF antibody therapy in rheumatoid Arthritis and the risk of serious infections and malignancies. *JAMA* 2006; 295: 2275-2285.
8. Biancone L, Orlando A, Kohn A, et al. Infliximab and newly diagnosed neoplasia in Crohn's disease: a multicenter matched pair study. *Gut* 2006; 55: 228-233.
9. Chakravarty EF, Michaud K, Wolfe F. Skin cancer, rheumatoid arthritis, and tumor necrosis factor inhibitors. *J Rheumatol* 2005; 32: 2130-2135.
10. Askling J, Forel CM, Brand L, et al. Risks of solid cancers in patients with rheumatoid arthritis and after treatment with tumor necrosis factor antagonists. *Ann Rheum Dis* 2005; 64: 1421-1430.
11. Lebowitz M, Blum R, Berkowitz E, et al. No evidence for increased risk of cutaneous squamous cell carcinoma in patients with rheumatoid arthritis receiving etanercept for up to 5 years. *Arch Dermatol* 2005; 141: 861-864.
12. Hrycaj P, Korczowska I, Łącki JK. Severe Parkinson's disease in rheumatoid arthritis patient treatment with infliximab. *Rheumatology* 2003; 42: 702-703.