

# Systemic lupus erythematosus of the urinary tract: focus on lupus cystitis

Sławomir Liberski<sup>1</sup>, Daria Marczak<sup>1</sup>, Ewelina Mazur<sup>1</sup>, Kacper Miętkiewicz<sup>1</sup>, Kamil Leis<sup>1</sup>,  
Przemysław Gałązka<sup>2</sup>

<sup>1</sup>Faculty of Medicine, Ludwik Rydygier *Collegium Medicum* in Bydgoszcz, Nicolaus Copernicus University in Toruń, Bydgoszcz, Poland

<sup>2</sup>Department of General and Oncological Surgery for Children and Adolescents, Faculty of Medicine, Ludwik Rydygier *Collegium Medicum* in Bydgoszcz, Nicolaus Copernicus University in Toruń, Bydgoszcz, Poland

## Abstract

Systemic lupus erythematosus (SLE) frequently manifests as urinary tract disease, most commonly in the form of lupus nephritis. Bladder involvement in the disease course takes a subclinical form and may affect both children and adults. Lupus cystitis can precede SLE diagnosis and may present with very unspecific urinary and digestive tract symptoms or no symptoms at all. The exact mechanism of bladder inflammation in lupus is not fully understood; however, histopathological studies suggest a possible role of immune complex-mediated small vessel vasculitis. Lupus cystitis is a rare SLE manifestation, but poses a challenge for physicians, due to its complex diagnostics and treatment.

**Key words:** systemic lupus erythematosus, urinary tract, lupus cystitis.

## Introduction

Systemic lupus erythematosus (SLE) is an autoimmune disease associated with the production of specific autoantibodies against DNA, histones and neutrophil proteins [1–4]. It is characterized by a fluctuating course of remissions and exacerbations [5]. Systemic lupus erythematosus frequently manifests as urinary tract disease. The most characteristic is renal involvement and consequently secondary lupus nephritis [6]. This is caused by the direct action of antibodies and the deposition of immune complexes in the glomeruli. In lupus development, interstitial cystitis may also occur [1–4]. Lupus cystitis is a rare complication of SLE but may lead to permanent bladder dysfunction, and its complications may include irreversible impairment of renal function [7]. In 20–60% of patients with SLE, there occurs glomerulonephritis, which is defined as lupus nephritis or lupus nephropathy. Such cases are associated with increased mortality and worse prognosis. Kidney involvement in lupus is clearly correlated with ethnicity: the highest risk is found in Afro-Americans (40–69%) and Asians

(47–53%), while in Caucasian patients the risk is lower (12–33%). Bladder involvement in the course of SLE is relatively rare [7]. It is estimated that it may affect 0.01–2% of all lupus patients, of whom 92% are women [3, 4, 8, 9].

## Systemic lupus erythematosus of the urinary tract

### Pathogenesis

Patients with SLE create antibodies mainly against chromatin and neutrophil proteins (lactoferrin, myeloperoxidase, proteinase-3, and elastase), which are commonly referred to as anti-neutrophil cytoplasmic antibodies (ANCA). Antigens and antibodies form immunological complexes, and their deposition in the glomerulus is associated with the development of lupus nephritis. The presence of immune complexes causes stimulation of the complement system cascade, which directly or indirectly (through the release of cytokines and proinflammatory chemokines) causes damage to the kidney structure. The glomerulus sclerotizes, and

---

### Address for correspondence:

Sławomir Liberski, Faculty of Medicine, Ludwik Rydygier *Collegium Medicum* in Bydgoszcz, Nicolaus Copernicus University in Toruń, 13 Jagiellońska St., 85-067 Bydgoszcz, Poland, e-mail: [liberski@o2.pl](mailto:liberski@o2.pl)

Submitted: 10.06.2018; Accepted: 25.07.2018

focal inflammation and fibrosis occur in the tubulointerstitial tissue [1, 2, 4, 10].

### Risk factors

Although the etiology of SLE is not fully understood, some of the risk factors are known. One of the most important is the female gender – women suffer from this disease 8–12 times more often. Estrogens are thought to play a role in the development of lupus. Increased expression of tissue compatibility antigens (HLA-DR2, HLA-DR3, HLA-B8) and acquired and congenital complement deficiencies also increase the risk of developing the disease. The presence of antiphospholipid antibodies correlates with a more severe course of lupus nephritis and faster progression to kidney failure. Increased risk is also caused by environmental factors (e.g. ultraviolet radiation, stress), and some drugs (e.g. hydralazine and procainamide). Infectious factors, including retroviruses and tuberculosis, are also likely to be involved in the development of the disease, although this has not yet been confirmed [10–12].

### Symptoms

Lupus nephritis should be suspected in patients with impaired renal function, the presence of proteinuria or active urinary sediment. If any symptoms of kidney involvement occur, a kidney biopsy should be performed. It should be done within one month of diagnosis and before the implementation of immunosuppressive therapy [3, 4].

### Lupus cystitis

Lupus cystitis more frequently presents in its subclinical than typical (full-blown) form, which may lead to

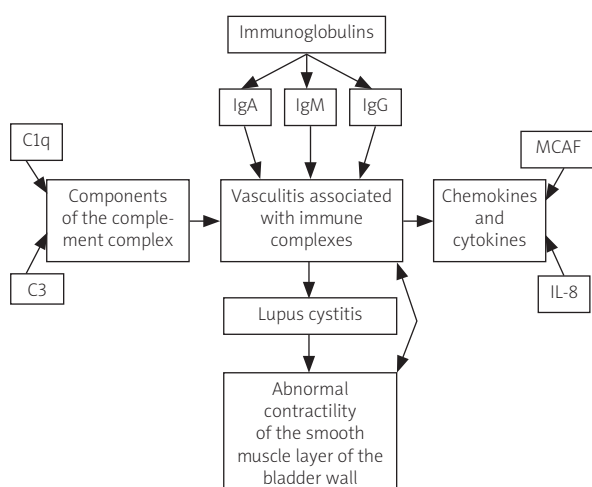


Fig. 1. Pathogenesis of lupus cystitis.

an underestimation of the number of patients affected by this disorder [13]. Cases of lupus cystitis have been described in both adults and children [14, 15]. The occurrence of lupus cystitis may precede the SLE diagnosis in the patient [16]. During the course of the disease, a progressive decrease in the bladder capacity is observed as a result of the bladder fibrosis, as well as the thinning of its wall [17]. Early diagnosis and initiation of glucocorticosteroid therapy are associated with a relatively good prognosis [16]. Delayed diagnostics and the lack of proper treatment may result in irreversible dysfunction of the urinary bladder [18]. A serious consequence of lupus cystitis is hydronephrosis, most often arising as a result of the vesicoureteral outlet narrowing caused by inflammatory swelling and fibrosis [19, 20]. Prolonged obstructive uropathy, without the proper intervention ensuring urinary outflow from the pelvicalyceal system, may result in irreversible kidney damage [17]. Abdominal and pelvic computed tomography can be used in both diagnostics and monitoring of lupus cystitis complications (i.e. hydronephrosis, hydronephrosis). Other frequent abdominal and pelvic CT findings are bladder wall thickening and decrease in bladder capacity, bowel wall thickening, ascites, target sign and comb sign [21, 22].

### Pathogenesis

The exact mechanism of bladder inflammation in the course of lupus is not fully understood [9]. Vasculitis associated with immune complexes is thought to have a decisive role in the pathomechanism of this disease (Fig. 1). Histopathological examination of bladder tissue obtained by biopsy in patients with lupus cystitis showed the presence of immunoglobulin IgA, IgG, IgM, as well as complement components C1q and C3 along the walls of the small vessels of the bladder. In addition to the presence of deposits of immune complexes, co-existing infiltrates of mononuclear leukocytes have also been found [8]. In addition to leukocytic infiltrates along the vessel walls, Sagawa et al. also observed increases in MCAF concentration and proinflammatory IL-8 in the urine of a patient with lupus cystitis, which indicates the important role of cytokines in the pathogenesis of lupus cystitis and implies a therapeutic benefit in the treatment of this complication with glucocorticosteroids [9]. Dyskinesia of the smooth muscle of the bladder in the course of lupus cystitis is caused by immunological mechanisms. The smooth muscle contractility is the aforementioned vasculitis associated with immune complexes [13, 18].

### Risk factors

Nishizaki et al. [16] stated that the presence of anti-dsDNA antibodies is a potential risk factor for lupus

cystitis and occurs in 76.1% of patients. They also noted that in 90.7% of cases the patients were female, so it may be a predisposing factor [16]. It was noted that in the group of patients with previously diagnosed SLE, the risk of developing lupus vulvitis is similar [20]. There is a positive correlation between the occurrence of lupus cystitis and CNS lupus, as well as lupus enteritis [9]. Different characteristics of risk factors were observed in the group of Japanese patients. In this group of patients, a positive correlation was observed between vomiting/age and the risk of lupus cystitis. The Japanese population also showed a weaker relationship between bladder involvement and the occurrence of CNS lupus [16]. The presence of anti-SSA antibodies in the serum and the occurrence of lupus cystitis in the group of Chinese patients were considered as non-specific [20].

### Symptoms

The first symptoms of lupus cystitis may be symptoms from both the urinary and the digestive system. It was noted that more often the symptoms appearing first are gastrointestinal [23]. Patients may present symptoms such as abdominal pain, watery diarrhea, constipation, and nausea, which may result in vomiting [7, 20]. These symptoms may lead to weight loss [3, 24]. A rash is less likely diagnosed. There were also cases in which the symptoms included fever and a joint pain [15, 20]. Predominant urinary tract symptoms are frequency and urgency [8]. Patients often report pain or discomfort located in the suprapubic area [20, 25]. Pollakiuria and lower abdominal pain are present in patients with urinary bladder manifestations (decreasing during micturition) [3, 24]. Nocturia and dysuria may also occur [20, 24]. In advanced cases, gastrointestinal hemorrhage, paralytic intestinal obstruction or perforation may occur [3, 24]. Urine analysis in patients with lupus cystitis usually does not show abnormalities [3]. The occurrence of haematuria has been reported [20]. The results of cytological examination are also negative, which makes diagnosis much more difficult [3].

However, it is important to mention that lupus cystitis may develop without noticeable clinical symptoms, especially in the urinary system, which may additionally be masked by other ailments associated with the course of lupus or concomitant diseases [20]. Rapid implementation of treatment is extremely important in this case due to the risk of hydronephrosis development and, consequently, renal failure [3].

### Treatment

There is no specific algorithm for lupus cystitis treatment. Only case reports are available in the literature.

Steroids such as methylprednisolone and prednisolone, as well as immunosuppressive drugs such as mycophenolate mofetil, have been used in the therapy of the disease. The applied model of pharmacotherapy of lupus cystitis is "pulse therapy". Yagita et al. described a case where a patient was treated intravenously with methylprednisolone in the initial dose of 1000 mg, followed by 100 mg, later orally with prednisone 40 mg/day followed by 35 mg/day and intravenous cyclophosphamide in a dose of 1100 mg (with the co-occurrence of enteritis and lupus erythematosus) [18].

On the other hand, Segawa et al. [9] presented a case of lupus cystitis, in which a combination therapy was applied as pulse therapy with methylprednisolone at a dose of 1000 mg and prednisone at a dose of 20 mg, which was then reduced to 10 mg. The effective pulse therapy of lupus cystitis was also described by Nishizaki et al. [16]. They used prednisolone at a dose of above 15 mg, which was accompanied by immunosuppressive substances such as mycophenolate mofetil or cyclophosphamide. After improvement of the patient's clinical condition, the prednisolone dose was reduced to 10 mg and cetirizine hydrochloride was added to the therapy. These researchers also described another case of lupus cystitis and the use of pulse therapy. In pharmacotherapy, methylprednisolone at a dose of 20 mg was used (the drug was used intravenously, 3 times a day), which was then halved after improvement of the clinical condition [16].

Mukhopadhyay et al. [7] in 2014 described a case of bladder manifestation of lupus occurring in a 20-year-old patient in whom pulse therapy was applied, with methylprednisolone in combination with cyclophosphamide in a six-cycle regimen (methylprednisolone at a dose of 1 g/day, administered three days in a cycle; cyclophosphamide 500 mg/day, administered one time per cycle). Prednisolone was used in the intervals between the cycles. Later, after the reduction of symptoms, azathioprine was also added [7].

Abelha-Alexio et al. [17] in 2015 presented a case of a generalized form of lupus erythematosus with bladder involvement. Their patient was previously treated with prednisolone, hydroxyquinone and azathioprine. After admission to the hospital and diagnosis of lupus cystitis with stage IV nephropathy, gastrointestinal tract involvement and *E. coli* infection with complications in the form of opportunistic infections and febrile neutropenia, methylprednisolone, mycophenolate mofetil, calcium and vitamin D pharmacotherapy was modified by adding rituximab, cyclophosphamide, acetylsalicylic acid, losartan, rosuvastatin, sertraline and pantoprazole. Plasmapheresis sessions were also performed. After one year, the patient regained full bladder function [17].

## Conclusions

Lupus cystitis is a rare, but very important SLE complication, due to the possibility of developing irreversible loss of renal and bladder function. Proper diagnosis, sometimes difficult in the presence of unspecific symptoms, is a key for adequate therapy implementation. A better understanding of this disease can lead to an increase in early diagnosis and may contribute to the creation of new effective therapeutic methods.

*The authors declare no conflict of interest.*

*The rights revenue was paid by Stowarzyszenie Zbiorowego Zarządzania Prawami Autorskimi Twórców Dzieł Naukowych i Technicznych KOPIPOL of Kielce from fees collected pursuant to Article 20 and Article 20<sup>1</sup> of the Copyright and Neighbouring Rights Act.*

*Wynagrodzenie autorskie sfinansowane zostało przez Stowarzyszenie Zbiorowego Zarządzania Prawami Autorskimi Twórców Dzieł Naukowych i Technicznych KOPIPOL z siedzibą w Kielcach z opłat uzyskanych na podstawie art. 20 oraz art. 20<sup>1</sup> ustawy o prawie autorskim i prawach pokrewnych.*

## References

- Caligaris-Cappio F, Bergui L, Tesio L, et al. HLA-Dr+ T cells of the Leu 3 (helper) type infiltrate the kidneys of patients with systemic lupus erythematosus. *Clin Exp Immunol* 1985; 59: 185-189.
- Hakkim A, Fűrnrrohr BG, Amann K, et al. Impairment of neutrophil extracellular trap degradation is associated with lupus nephritis. *PNAS* 2010; 107: 9813-9818.
- Koike T, Takabayashi K. Lupus Cystitis in the Japanese. *Intern Med* 1996; 35: 87-88.
- Idasiak-Piechocka I, Perkowska-Ptasińska A. Toczeń rumieniowaty układowy (TRU). *Nefrol Dial Pol* 2016; 20: 93-99.
- Doria A, Zen M, Iaccarino L. Remission in SLE: the duration depends on multiple factors, including the definition. *Ann Rheum Dis* 2016; 75: e77.
- Lech M, Anders HJ. The pathogenesis of lupus nephritis. *J Am Soc Nephrol* 2013; 24: 1357-1366.
- Mukhopadhyay S, Jana S, Roy MK, et al. Lupus cystitis: An unusual presentation of systemic lupus erythematosus. *Indian J Nephrol* 2014; 24: 308-311.
- Georgin-Lavialle S, Izzedine H, Launay-Vacher V, et al. Why is a shrunken bladder and a nephrotic kidney an expression of the same disease? *Nephrol Dial Transplant* 2004; 19: 3193-3195.
- Segawa C, Wada T, Furuichi K, et al. Steroid pulse therapy in lupus cystitis. *Intern Med* 1996; 35: 155-158.
- Klaska I, Nowak JZ. Rola układu dopętniacza w fizjologii i patologii. *Post Hig Med Dosw* 2007; 61: 167-177.
- Majdan M. Nerki a zespół antyfosfolipidowy. *Pol Arch Med Wewn* 2007; 117: 55-58.
- Cameron JS. Lupus Nephritis. *J Am Soc Nephrol* 1999; 10: 413-424.
- Al-Shibli A, Al-Salam S, Bernieh B, et al. Lupus cystitis in an Omani girl. *Saudi J Kidney Dis Transpl* 2010; 21: 943-946.
- do Socorro Teixeira Moreira Almeida M, Carvalho LL, Carvalho AG, et al. Interstitial cystitis and systemic lupus erythematosus in a 20-year-old woman. *Rheumatol Int* 2008; 29: 219-221.
- Kurosawa R, Miyamae T, Imagawa T. A case of childhood systemic lupus erythematosus complicated with lupus cystitis. *Nihon Rinsho Meneki Gakkai Kaishi* 2006; 29: 154-159.
- Nishizaki Y, Tamaki H, Yukawa S, et al. Comparison between Japanese and non-Japanese features of lupus cystitis based on case reports including novel therapy and a literature review. *Intern Med* 2011; 50: 961-968.
- Abelha-Aleixo J, Moura M, Bernardo A, et al. Lupus cystitis and repercussions of delayed diagnosis. *Acta Reumatol Port* 2015; 40: 294-298.
- Yagita M, Tsujimoto K, Yagita M, Masaaki F. Atypical Presenting Symptoms of Acute Onset Systemic Lupus Erythematosus with Enteritis and Cystitis. *Case Rep Med* 2016; Article ID 8579812. Doi: <https://doi.org/10.1155/2016/8579812>
- Hong S, Kim YG, Ahn SM, et al. Clinical outcomes of hydro-nephrosis in patients with systemic lupus erythematosus. *Int J Rheum Dis* 2016; 19: 1317-1321.
- Zhang G, Li H, Huang W, et al. Clinical features of lupus cystitis complicated with hydroureteronephrosis in a Chinese population. *J Rheumatol* 2011; 38: 667-671.
- Kirby JM, Jhaveri KS, Maizlin ZV, et al. Abdominal manifestations of systemic lupus erythematosus: spectrum of imaging findings. *Can Assoc Radiol J* 2009; 60: 121-132.
- Min JK, Byun JY, Lee SH, et al. Urinary bladder involvement in patients with systemic lupus erythematosus: with review of the literature. *Korean J Intern Med* 2000; 15: 42-50.
- Shimizu A, Tamura A, Tago O, et al. Lupus cystitis: a case report and review of the literature. *Lupus* 2009; 18: 655-658.
- Nakauchi Y, Suehiro T, Tahara K, et al. Systemic lupus erythematosus relapse with lupus cystitis. *Clin Exp Rheumatol* 1995; 13: 645-648.
- Akitake R, Nakase H, Ueno S, et al. Involvement of lupus enteritis in a patient with lupus cystitis and nephritis. *Digestion* 2009; 80: 160-164.